

# *Copper dressing resulting in increased oxygen levels in wound and surrounding skin*

## *A case series study*

Alexandra H.J. Janssen, PhD, MANP, Wound Care, Department of Surgery, Elkerliek Hospital, Helmond, the Netherlands

Yvonne H.P. Siebers, RN, Woundcare, Department of surgery, VieCuri Hospital, Venlo, the Netherlands

EWMA 2024

Disclosure: we We have no financial disclosure or conflict of interest with the presented material in this poster presentation.

# Introduction

- › Approximately 1 to 2 % of the population will experience a hard-to-heal wound during their lifetime.<sup>1</sup>
- › Several studies indicate the effectiveness of Copper in terms of enhanced wound healing and infection control.<sup>2-4</sup>
- › As known, oxygen plays an important role in the reconstruction of new vessels and connective tissue, as well as the migration of epithelial cells, and it allows for normal local metabolism while facilitating resistance to infection.<sup>5</sup>
- › A recent (in the Netherlands) launched Copper dressing\* is claimed to increase oxygen levels in the wound and the surrounding skin,<sup>6</sup> but up to now there is no clear evidence to support this claim.
- › Therefore, this case series aimed to describe the effects on oxygen saturation levels of the skin of patients with wounds treated with a copper oxide impregnated wound dressing.

<sup>1</sup>Gottrup, F., et al., *A new concept of a multidisciplinary wound healing center and a national expert function of wound healing*. Arch Surg, 2001. **136**(7): p. 765-72.

<sup>2</sup>Gorel, O., et al., *Enhanced healing of wounds that responded poorly to silver dressing by copper wound dressings: Prospective single arm treatment study*. Health Sci Rep, 2024. **7**(1): p. e1816.

<sup>3</sup>Melamed, E., et al., *Stimulation of Healing of Non-Infected Stagnated Diabetic Wounds by Copper Oxide-Impregnated Wound Dressings*. Medicina (Kaunas), 2021. **57**(10).

<sup>4</sup>Melamed, E., et al., *Healing of Chronic Wounds by Copper Oxide-Impregnated Wound Dressings-Case Series*. Medicina (Kaunas), 2021. **57**(3).

<sup>5</sup>Frykberg, R., et al., *Use of Topical Oxygen Therapy in Wound Healing*. J Wound Care, 2023. **32**(Sup8b): p. S1-s32.

<sup>6</sup>Borkow, G., et al., *Molecular mechanisms of enhanced wound healing by copper oxide-impregnated dressings*. Wound Repair Regen, 2010. **18**(2): p. 266-75.

\* MedCu©, MedCu Technologies, Tel Aviv

# Method

- › This multicenter case series study prospectively recruited 15 consecutive patients treated in two teaching hospitals in the Netherlands.
- › Patients were eligible if they had a wound  $> 1 \text{ cm}^2$ , over 3 weeks in duration and provided written and verbal informed consent regarding participating in this study and taking pictures of the wound.
- › Before start of the wound treatment with the copper dressing, and at every outpatient clinic visit, a scan with a hyperspectral camera\* was performed.
- › The hyperspective imaging technology of the hyperspectral camera, presents tissue oxygen saturation at 1 mm in depth of the skin, tissue Hemoglobin index, near infra-red index (oxygenation saturation of the skin in 5 mm of depth) and the tissue water index in the superficial skin.<sup>1</sup>

<sup>1</sup>Website Protex Healthcare. 2019 [cited 2024 april 6];  
Available from: <https://www.protexhealthcare.com/>

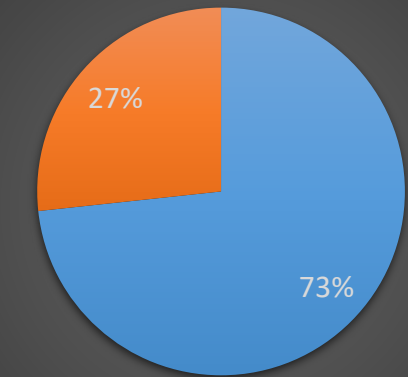
\* TIVITA©, Protex Healthcare, Belgium

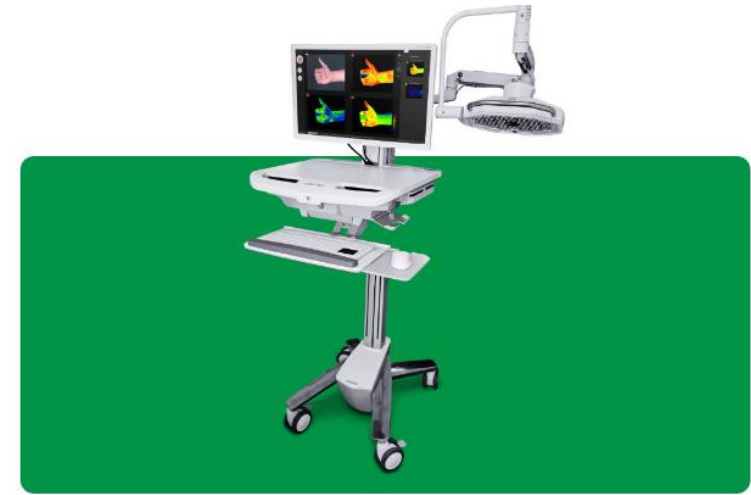

Table 1 Baseline Characteristics

	Gender	Age	Wound etiology / location	Smoking	DM	CVA /TIA	HF	Malignancy	PAOD	CVI	Previous relevant Intervention(s)
1	Female	90	Lower leg left after excision squamous cell carcinoma	No	Yes	No	Yes	No (excised)	No	No	5-7-2023 Excision squamous cell carcinoma
2	Female	49	In old burn scar, shoulder right	No	No	No	No	No	No	No	None
3	Female	79	Postoperatively infected wound left knee	No	No	No	No	No	No	Yes	24-10-2024 USCT VSM both legs
4	Male	72	Ankle left medial and right lateral, in old scar	No	No	Yes	No	No	Yes, limited	Yes	2012 trauma legs, surgery 2021 USCT VSM right
5	Male	47	Shine right, trauma	Yes	No	No	No	No	No	Yes	2019 EVLT VSM right
6	Male	80	Hallux foot right	No	Yes	No	Yes	No	Yes	No	09-09-2022 amputation TMT V left
7	Female	88	Calf left leg	No	No	No	No	No	Yes	Yes	Venous interventions in past
8	Female	69	Lower leg right	No	Yes	No	No	No	No	No	None
9	Female	61	After excision neuroma MT V left	No	No	No	Yes	No	No	No	7-12-2023 excision neuroma MT V left
10	Female	77	Ankle medial right	No	No	Yes	Yes	No	No	Yes	None
11	Male	78	Shine right	No	No	No	No	No	Yes	Yes	30-6-2022 EVLT VSM right
12	Female	82	Shine left	No	No	No	No	No	No	No	None
13	Female	94	Lower back	No	No	No	No	No	No	No	None
14	Female	60	Left foot medial	No	No	No	No	No	No	Yes	2011 RFA
15	Female	74	Left leg lateral	No	No	No	No	No	No	No	None

After use of Copper dressing



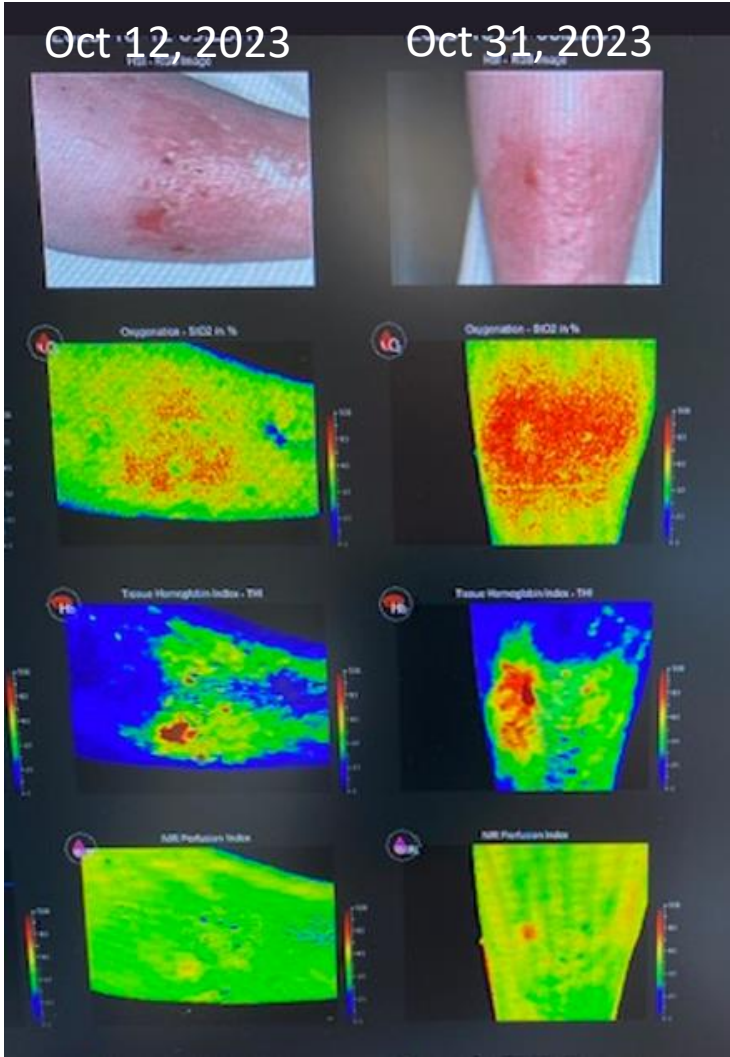
■ Increase in Oxygen levels (%)  
■ No increase in oxygen levels (%)

Results

StO2 %  
(Oxygen saturation at 1 mm in depth of the skin) ->

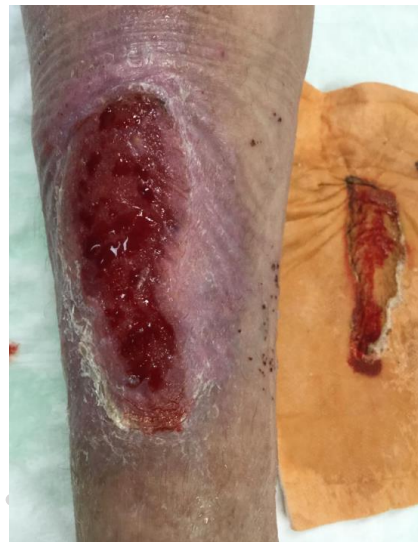THI (Tissue Hemoglobin Index)->

NIR (oxygenation saturation of the skin in 5 mm of depth of the skin) ->



# Discussion

- › 73% of the patients treated with the Copper dressing\* showed increased oxygen levels, at 1 mm in depth of the skin and/or 5 mm in depth of the skin
- › Therefore, in case of infected wounds an/or wounds with decreased oxygen levels, this Copper dressing\* can be a valuable treatment option
- › Further studies are needed to provide evidence on healing properties and conformation of our results of increased oxygenation levels of this Copper dressing\*



\* MedCu©, MedCu Technologies, Tel Aviv